

Dynamic synchronisation of central oscillators in essential tremor

B. Hellwig^{a,*}, B. Schelter^b, B. Guschlbauer^a, J. Timmer^b, C.H. Lücking^a

^aNeurologische Universitätsklinik, Neurozentrum, Breisacher Strasse 64, 79106 Freiburg, Germany

^bZentrum für Datenanalyse und Modellbildung, Eckerstrasse 1, 79104 Freiburg, Germany

Accepted 4 April 2003

Abstract

Objective: Coherence analysis of electromyography (EMG) signals in essential tremor (ET) suggests that tremor in the right and left arm is induced by independent central oscillators. The sensorimotor cortex seems to be part of the tremor-generating neuronal network in ET. Here, we investigated using electroencephalography (EEG) whether the independence of central oscillators in ET is supported by the analysis of cortical activity.

Methods: In 8 patients with ET, bilateral hand tremor was activated by wrist extension. EMGs from the wrist flexors and extensors were recorded simultaneously with an EEG. EEG-EMG coherence was estimated for 74 epochs of 60 s duration.

Results: In 42.6% of the cases, EEG-EMG coherence at the tremor frequency existed only with the contralateral sensorimotor cortex. However, 21.6% of the tremor-EMGs were coherent with EEG activity over both the contralateral and ipsilateral sensorimotor cortex. Bilateral and exclusively contralateral EEG-EMG coherence could alternate within the same recording. Bilateral EEG-EMG coherence was associated with increased right-left EEG-EEG coherence, increased right-left EMG-EMG coherence as well as with increased tremor strength.

Conclusions: In ET, central oscillators in the right and left brain are not entirely independent of each other. They may dynamically synchronise, presumably by interhemispheric coupling via the corpus callosum.

© 2003 International Federation of Clinical Neurophysiology. Published by Elsevier Science Ireland Ltd. All rights reserved.

Keywords: Essential tremor; EEG-EMG coherence; Motor cortex; Oscillation; Interhemispheric interaction

1. Introduction

Essential tremor is a frequent movement disorder which is characterised by a postural tremor of the upper limbs. The tremor is typically bilateral, but not necessarily symmetric. Other body parts may also be tremulous, for instance the head, the chin, the trunk or the lower limbs. Cerebellar signs such as intention tremor may be present, other neurological abnormalities, however, do not occur (Deuschl et al., 1998).

The neurophysiological mechanisms leading to the clinical expression of essential tremor are not precisely known. There is, however, good evidence that essential tremor is of central origin (Elble, 1996, 2000). A number of structures seem to be involved in the tremor-generating oscillatory neuronal network. First, the olivocerebellar system appears to play an important role. This is supported

by animal experiments on harmaline-induced tremor which is considered as an animal model of essential tremor (Llinás and Volkind, 1973; Lamarre, 1984), as well as by functional imaging studies in human beings which have demonstrated increased glucose metabolism in the medulla oblongata (Hallett and Dubinsky, 1993) or increased blood flow in the cerebellum (Jenkins et al., 1993; Bucher et al., 1997). Second, there is evidence that the nucleus ventralis intermedialis, a cerebellar relay nucleus in the ventrolateral thalamus, is involved in the generation of essential tremor. Thalamic activity recorded during stereotactic operations in patients with essential tremor is strongly correlated with forearm electromyography (EMG) signals (Hua et al., 1998). Moreover, stereotactic lesions or high-frequency stimulation in the nucleus ventralis intermedialis have been shown to suppress essential tremor (Benabid et al., 1991; Schuurman et al., 2000). Third, the cerebral cortex seems to be part of the tremor-generating neuronal network. Coherence analysis of simultaneous electroencephalography (EEG) and EMG recordings in patients with unilaterally

* Corresponding author. Tel.: +49-761-270-5001; fax: +49-761-270-5338.

E-mail address: hellwigb@nz.ukl.uni-freiburg.de (B. Hellwig).

activated essential tremor revealed tremor-correlated activity in the contralateral sensorimotor cortex (Hellwig et al., 2001).

Considering the bilateral symmetric architecture of the brain and taking into account that essential tremor is typically bilateral, the question arises whether there is one common central oscillator or whether there are two separate oscillators, one in each half of the brain. Although tremor frequencies of the right and left arm may be very similar in essential tremor, analysis of EMG-EMG coherence did not reveal a significant right-left correlation (Lauk et al., 1999; Raethjen et al., 2000). This was considered as evidence that essential tremor is generated by independent central oscillators in the right and left brain.

However, the investigation of peripheral EMG activity provides only indirect insights into neurophysiological mechanisms in the central nervous system. A direct observation of brain activity would certainly be more conclusive. Therefore, we analysed in the present study EEG activity in bilaterally activated essential tremor. Following our previous study on unilaterally activated essential tremor (Hellwig et al., 2001), one would predict significant corticomuscular coherence between the sensorimotor cortex and contralateral muscles. Significant ipsilateral EEG-EMG coherence, however, should not occur given the presence of independent central oscillators in the right and left brain.

2. Methods

2.1. Patients

Eight patients (4 women, 4 men) with essential tremor participated in this study. They were selected because they showed a distinct postural tremor of both arms without significant head tremor. Apart from intention tremor in 3 patients, there were no further neurological abnormalities, particularly no Parkinsonian symptoms. Patients were on average 60 years old (range 44–74 years). Tremor had been present for at least 5 years (mean 15.6 years; range 5–30 years). Six patients were without medical treatment for tremor, one patient received 30 mg propranolol per day, another patient 500 mg primidone per day. Medical treatment was not changed before the recordings. The study protocol was approved by the local ethical committee of the University of Freiburg. All patients gave informed consent to participate in this investigation.

2.2. Recording procedure

Inside a dimly lit room, patients were seated in a comfortable chair with their forearms supported. Surface EMG electrodes were attached to the wrist flexors and extensors of both arms. EEG was recorded with a 64-channel EEG system (Neuroscan, Herndon, VA, USA). Patients were asked to keep their eyes open and to fix their eyes on a point

of light about 1.5 m away. Bilateral postural tremor was elicited by wrist extension on the right and left side. EEG and EMG signals were sampled at 1000 Hz and bandpass filtered (EEG 1–200 Hz, EMG 50–200 Hz). Data were stored on a personal computer and analysed off-line.

2.3. Data analysis

Each recording was divided into non-overlapping high quality epochs of 60 s duration. In all, 74 such epochs were analysed in the present study. According to the quality of the recording and to the patient's ability to co-operate, the number of epochs investigated per patient varied (between two and 15 per patient). The EMG was full-wave rectified. The potential field over the scalp was transformed into the reference free current density distribution (Hjorth, 1991) which has been shown to be the optimum basis for EEG-EMG coherence analysis (Mima and Hallett, 1999a).

In all, eight EEG electrodes were considered for data analysis, 4 over the left and 4 over the right frontocentral cortex (Fig. 1). These electrodes included C3 and C4 which are supposed to be situated over the hand areas of the right and left sensorimotor cortex. In a previous study on unilaterally activated essential tremor (Hellwig et al., 2001), corticomuscular coherences were particularly high for C3 and C4. In some cases, the above-mentioned study revealed also significant corticomuscular coherences at electrodes adjacent, i.e. anterior and/or medial to C3 and C4. Therefore, these electrodes (C1, C2, C1a, C2a, C3a, C4a) were also included in the data analysis.

Coherences between the rectified tremor EMGs of both arms and each of the 8 EEG channels mentioned above were estimated by cross-spectral methods (Priestley, 1989; Brockwell and Davis, 1991; Salenius et al., 1997; Timmer et al., 1998a,b; Halliday et al., 1998; Mima and Hallett,

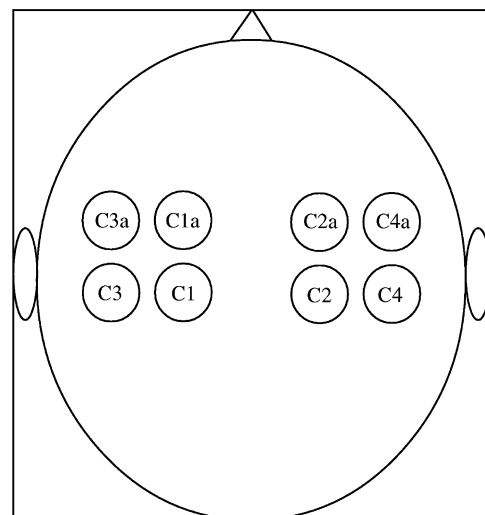


Fig. 1. Schematic layout of the 8 EEG electrodes over the right and left frontocentral cortex which were considered for data analysis.

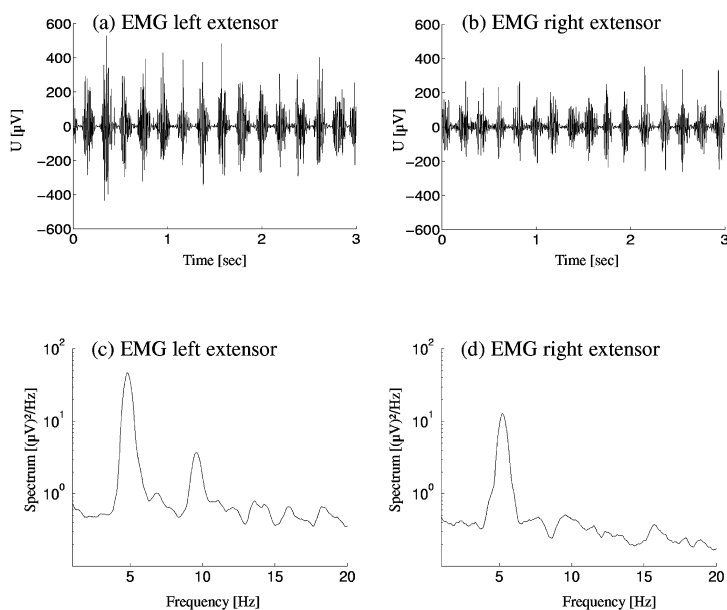


Fig. 2. (a, b) EMG traces of the right and left arm in a patient with bilaterally activated essential tremor. (c, d) The corresponding EMG autospectra.

1999b; Grosse et al., 2002). In each epoch, the highest EEG-EMG coherence found on each side was selected for further analysis. We investigated also right-left coherences between the tremor EMGs. Moreover, right-left coherences between the EEG channels over the frontocentral cortex illustrated in Fig. 1 were calculated. Here, we considered always those EEG channels with the highest EEG-EMG coherence. In cases without significant EEG-EMG coherence, the signal at the EEG electrodes C3 or C4 was used for the calculation of EEG-EEG coherence. Volume conduction as a possible source of spurious right-left EEG-EEG coherence was examined in two ways. First, the EEG-EEG coherence spectra were inspected for significant coherences over a broad range of frequencies assuming that volume conduction must involve a large frequency band. Second, we calculated the EEG-EEG cross-correlation which would be characterised by high and narrow peaks at time lag 0 ms in case of volume conduction (Raethjen et al., 2000).

Finally, we studied the signal-to-noise ratios (SNRs) of the tremor EMGs. SNRs can be considered as a measure of the tremor strength. They were calculated with the EMG autospectra by dividing the peak at the tremor frequency above the noise level by the noise level itself (Timmer, 1998).

3. Results

Figs. 2a,b display unrectified tremor EMGs of the left and right forearm extensor muscles in a patient with essential tremor who activated bilateral postural tremor by wrist extension. Tremor frequencies are at about 5 Hz in both arms. This is confirmed by the respective EMG autospectra which exhibit clear peaks at 5 Hz (Figs. 2c,d).

Using data from the same patient, Fig. 3 illustrates EEG-EMG coherence for two consecutive recording epochs of 60 s duration. In epoch I, there is highly significant corticomuscular coherence at the tremor frequency and its first harmonic between the left extensor and the contralateral frontocentral cortex (Fig. 3a). Coherence analysis does not reveal significant EEG-EMG coherence at the tremor frequency between the left extensor and the ipsilateral frontocentral cortex (Fig. 3b).

The presence of contralateral but not ipsilateral EEG-EMG coherence does, however, not seem to be a general rule. This is demonstrated by the analysis of recording epoch II. Again, there is highly significant

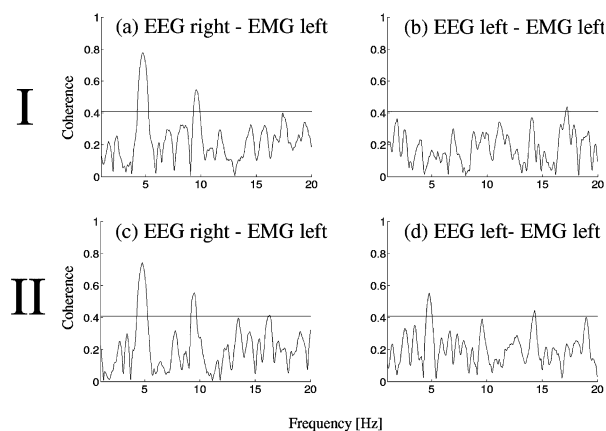


Fig. 3. (a, b) Recording epoch I. EEG-EMG coherence between the left arm and the contra- and ipsilateral cortex. The horizontal line at a coherence of about 0.4 indicates the level of significance ($P < 0.01$). (c, d) Recording epoch II (derived from the same patient and the same recording as in (a, b)). EEG-EMG coherence between the left arm and the contra- and ipsilateral cortex.

corticomuscular coherence at the tremor frequency and its first harmonic between the left extensor and the contralateral frontocentral cortex (Fig. 3c). There is indeed a distinct similarity between Figs. 3a and c. However, in contrast to the results shown in Fig. 3b, analysis of the EEG-EMG coherence between the left extensor and the ipsilateral frontocentral cortex reveals also significant values at the tremor frequency (Fig. 3d).

In summary, Fig. 3 illustrates in an example that exclusively contralateral EEG-EMG coherence and bilateral EEG-EMG coherence may occur in the same patient with bilaterally activated essential tremor. This alternation between contralateral and bilateral corticomuscular coherence was present in 6 of the 8 patients investigated here. In the 74 time series of 60 s duration studied, exclusively contralateral EEG-EMG coherence occurred in 42.6% of the cases, while bilateral EEG-EMG-coherence could be found in 21.6% of the cases (Fig. 4).

Closer inspection of Figs. 3c,d reveals that the contralateral EEG-EMG coherence at the tremor frequency is higher than the ipsilateral one. This seems to be a general tendency. In Fig. 5a, all significant contralateral and ipsilateral EEG-EMG coherences at the tremor frequency encountered in this study are illustrated. Contralateral EEG-EMG coherences tend to be higher than the ipsilateral ones, the difference being statistically significant ($P < 0.01$, Wilcoxon rank sum test). This finding is corroborated by comparing ipsi- and contralateral EEG-EMG coherences in those cases in which, as in Figs. 3c,d, bilateral EEG-EMG coherences were present. Ipsi- and contralateral EEG-EMG coherences were plotted against each other (Fig. 5b). In case of approximately equal values of ipsi- and contralateral EEG-EMG coherences, the dots in Fig. 5b should be scattered around the diagonal. However, the dots mainly fall below the diagonal confirming that contralateral EEG-EMG coherences tend to be higher than the ipsilateral ones.

We investigated also how contralateral or bilateral EEG-EMG coherences are related to EEG-EEG coherence and EMG-EMG coherence. Results are shown in Table 1. When comparing recording epochs with bilateral and exclusively contralateral EEG-EMG coherence, the percentage of

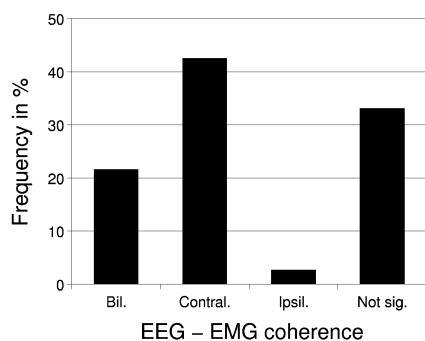


Fig. 4. Relative frequencies of bilateral, exclusively contralateral, exclusively ipsilateral and not significant EEG-EMG coherences.

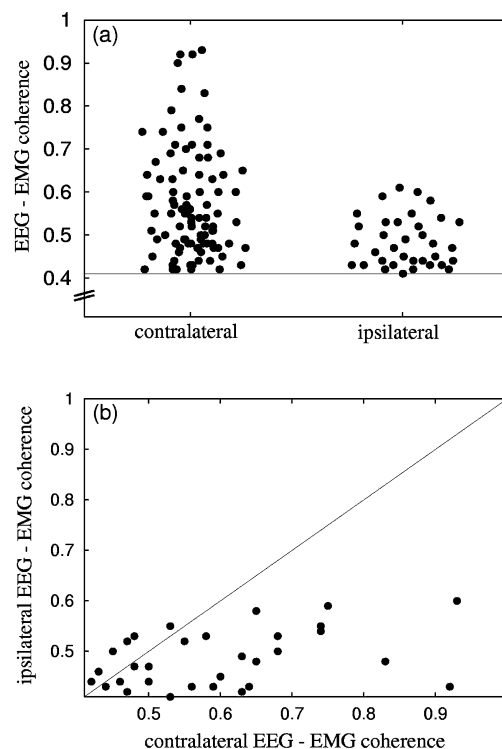


Fig. 5. (a) All contralateral and all ipsilateral EEG-EMG coherences encountered in this study. The horizontal line at a coherence of about 0.4 indicates the level of significance ($P < 0.01$). (b) For all cases of bilateral EEG-EMG coherence, the contralateral EEG-EMG coherences are plotted against the ipsilateral ones.

significant EEG-EEG coherence at the tremor frequency is more than 5 times higher in the bilateral case. In order to check for volume conduction as a cause of spurious EEG-EEG coherence, the coherence spectra were inspected for significant coherences over a broad range of frequencies. This was never the case. EEG-EEG coherence was rather restricted to narrow peaks at the tremor frequency. Additional consideration of the EEG-EEG cross-correlation (cf. Section 2 and Raethjen et al., 2000) revealed only one case in which EEG-EEG coherence due to cross-talk could not be safely excluded. Disregarding this case would not alter the results substantially, the frequency of significant EEG-EEG coherence at the tremor frequency in case of bilateral EEG-EMG coherence would be reduced to 31.2%. Table 1 reveals also that EMG-EMG coherence at the tremor frequency is distinctly more frequent in bilateral than in exclusively contralateral EEG-EMG coherence. Thus, bilateral EEG-EMG coherence seems to be associated with increased coupling between the right and left frontocentral cortex and the right and left tremulous arm.

In Fig. 6, the tremor strength in contralateral and bilateral EEG-EMG coherence is displayed. Signal-to-noise ratios (SNRs) calculated from the autospectra of the tremor EMGs (see Section 2) were used as a measure of the tremor amplitudes. Fig. 6 illustrates that the SNRs cover a wide range. They tend to be higher in recording epochs with

Table 1

Incidences of EEG-EEG coherence and EMG-EMG coherence at the tremor frequency ($P < 0.01$) in the cases of exclusively contralateral and bilateral EEG-EMG coherence at the tremor frequency ($P < 0.01$)

	EEG-EMG coherence	
	Bilateral	Contralateral
EEG-EEG coherence (%)	34.4	6.3
EMG-EMG coherence (%)	15.6	3.2

bilateral EEG-EMG coherence than in those with exclusively contralateral EEG-EMG coherence, the difference being statistically significant ($P < 0.01$, Wilcoxon rank sum test). This indicates that bilateral EEG-EMG coherence is associated with increased tremor amplitudes.

4. Discussion

A recent study on *unilaterally* activated essential tremor demonstrated significant coherence between the forearm muscles of the tremulous arm and the contralateral sensorimotor cortex (Hellwig et al., 2001). The present study tackled the issue of corticomuscular coherence in *bilaterally* activated essential tremor. Previous work on EMG-EMG coherence in bilaterally activated essential tremor did not provide evidence for a significant right-left correlation (Lauk et al., 1999; Raethjen et al., 2000). Therefore, it was assumed that independent central oscillators are responsible for the tremor in the right and left arm. Similar conclusions have been drawn for Parkinsonian tremor (Lauk et al., 1999; Raethjen et al., 2000; Hurtado et al., 2000; Ben-Pazi et al., 2001). Based on these studies on EMG-EMG coherence, there was a clear prediction about corticomuscular coherence in bilaterally activated essential tremor: the activity in each tremulous arm should only be coherent with the contralateral sensorimotor cortex, but not with the ipsilateral one.

The present study confirmed this prediction only to some extent. In 42.6% of the cases investigated, coherence existed indeed exclusively between the tremulous arm and the contralateral cortex. However, in contrast to the prediction, significant EEG-EMG coherence with both the contra- and ipsilateral cortex was found in 21.6% of the cases. EEG-EMG coherence could switch between the exclusively contralateral and the bilateral condition within the same recording.

There is no indication that bilateral EEG-EMG coherence was simply due to volume conduction in the brain. First, we did not encounter bilateral corticomuscular coherence when essential tremor was activated only unilaterally (Hellwig et al., 2001). Second, closer investigation of EEG-EEG coherence did not indicate that volume conduction played a major role (cf. Section 3). Third, bilateral

EEG-EMG coherence was associated with increased right-left EMG-EMG coherence. Cross-talk between muscles of the right and left arm can be positively excluded.

How does EEG-EMG coherence switch from the exclusively contralateral condition to the bilateral one? The involvement of ipsilateral corticospinal connections is unlikely. The increased incidence of significant EEG-EEG coherence between the right and left cortex in the case of bilateral EEG-EMG coherence indicates rather that interhemispheric coupling plays an important role. Presumably, a pool of cortical neurons coherently active with the contralateral tremulous arm is able to induce coherent oscillations also in the opposite hemisphere via reciprocal callosal connections. Interhemispheric synchronisation of cortical oscillatory activity has indeed been described. It was first shown by Engel et al. (1991) who studied neuronal activity in homologous areas of the cat visual cortex. These authors provided also evidence that interhemispheric synchronisation is mediated via the corpus callosum and not by subcortical structures. Murthy and Fetz (1996) extended these findings to the sensorimotor cortex of monkeys. They showed that oscillatory local field potentials and associated spike activity in the precentral areas of both hemispheres could become synchronised when the monkey made bimanual movements. This was corroborated by Cardoso de Oliveira et al. (2001) who found task-specific neural interactions between the motor cortical areas of monkeys during bimanual movements. The degree of interhemispheric correlation could change rapidly during the execution of the task. For human beings, functional coupling of the right and left sensorimotor cortex has also been shown. Andres et al. (1999) found that interhemispheric coherence was increased during the learning of a bimanual task.

In summary, there is good experimental evidence for interhemispheric coupling of cortical motor areas during the execution of bimanual voluntary movements. This physiological mechanism seems to have some importance also in the pathological condition of bilaterally activated essential tremor. Interhemispheric coupling does, however, not mean that the involvement of the two hemispheres is evenly

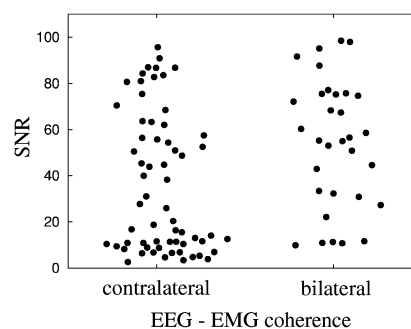


Fig. 6. SNRs of the tremor EMGs in bilateral and exclusively contralateral EEG-EMG coherence. SNRs in cases of bilateral EEG-EMG coherence are significantly higher ($P < 0.01$).

balanced. In the present study, contralateral EEG-EMG coherence tended to be higher than the ipsilateral one. Moreover, bilateral EEG-EMG coherence was not a stable phenomenon. Within the same recording, exclusively contralateral and bilateral EEG-EMG coherence could alternate. In other words, there seemed to be a dynamic synchronisation and desynchronisation of the tremor generating oscillators in the right and left brain. A similar phenomenon has been observed using dual microelectrode recordings in the globus pallidus of a Parkinsonian patient (Hurtado et al., 1999). Pallidal neurons firing in synchrony with upper limb tremor could fluctuate between states of independence and transient interneuronal coupling.

It should be emphasised that the occurrence of bilateral EEG-EMG coherence has a clinical correlate. There is an association with increased signal-to-noise ratios in the EMG autospectra, i.e. tremor amplitudes increase with bilateral EEG-EMG coherence. It remains, however, an open question if the interhemispheric coupling of cortical motor areas enhances essential tremor, or if, vice versa, increased tremor amplitudes induce interhemispheric coherence by a more prominent proprioceptive input to the sensorimotor cortex. Both mechanisms need not be mutually exclusive. They may reinforce each other via positive feedback.

References

- Andres FG, Mima T, Schulman AE, Dichgans J, Hallett M, Gerloff C. Functional coupling of human cortical sensorimotor areas during bimanual skill acquisition. *Brain* 1999;122:855–70.
- Benabid AL, Pollak P, Gervason C, Hoffmann D, Gao DM, Hommel M, Perret JE, de Rougemont J. Long-term suppression of tremor by chronic stimulation of the ventral intermediate thalamic nucleus. *Lancet* 1991; 337:403–6.
- Ben-Pazi H, Bergman H, Goldberg JA, Giladi N, Hansel D, Reches A, Simon ES. Synchrony of rest tremor in multiple limbs in Parkinson's disease: evidence for multiple oscillators. *J Neural Transm* 2001;108: 287–96.
- Brockwell PJ, Davis RA. *Time series: theory and methods*. New York: Springer; 1991.
- Bucher SF, Seelos KC, Dodel RC, Reiser M, Oertel WH. Activation mapping in essential tremor with functional magnetic resonance imaging. *Ann Neurol* 1997;41:32–40.
- Cardoso de Oliveira S, Gribova A, Donchin O, Bergman H, Vaadia E. Neural interactions between motor cortical hemispheres during bimanual and unimanual arm movements. *Eur J Neurosci* 2001;14: 1881–96.
- Deuschl G, Bain P, Brin M, and an Ad Hoc Scientific Committee. Consensus statement of the Movement Disorder Society on tremor. *Mov Disord* 1998;13:2–23.
- Elble RJ. Central mechanisms of tremor. *J Clin Neurophysiol* 1996;13: 133–44.
- Elble RJ. Origins of tremor. *Lancet* 2000;355:1113–4.
- Engel AK, König P, Kreiter AK, Singer W. Interhemispheric synchronization of oscillatory neuronal responses in cat visual cortex. *Science* 1991;252:1177–9.
- Grosse P, Cassidy MJ, Brown P. EEG-EMG, MEG-EMG and EMG-EMG frequency analysis: physiological principles and clinical applications. *Clin Neurophysiol* 2002;113:1523–31.
- Hallett M, Dubinsky RM. Glucose metabolism in the brains of patients with essential tremor. *J Neurol Sci* 1993;114:45–8.
- Halliday DM, Conway BA, Farmer SF, Rosenberg JR. Using electroencephalography to study functional coupling between cortical activity and electromyograms during voluntary contractions in humans. *Neurosci Lett* 1998;241:5–8.
- Hellwig B, Häussler S, Schelter B, Lauk M, Guschlbauer B, Timmer J, Lücking CH. Tremor-correlated cortical activity in essential tremor. *Lancet* 2001;357:519–23.
- Hjorth B. Principles for transformation of scalp EEG from potential field into source distribution. *J Clin Neurophysiol* 1991;8:391–6.
- Hua SE, Lenz FA, Zirh TA, Dougherty PM. Thalamic neuronal activity correlated with essential tremor. *J Neurol Neurosurg Psychiatry* 1998; 64:273–6.
- Hurtado JM, Gray CM, Tamas LB, Sigvardt KA. Dynamics of tremor-related oscillations in the human globus pallidus: a single case study. *Proc Natl Acad Sci USA* 1999;96:1674–9.
- Hurtado JM, Lachaux JP, Beckley DJ, Gray CM, Sigvardt KA. Inter- and intralimb coupling in Parkinsonian tremor. *Mov Disord* 2000;15: 683–91.
- Jenkins IH, Bain PG, Colebatch JG, Thompson PD, Findley LJ, Frackowiak RSJ, Marsden CD, Brooks DJ. A positron emission tomography study of essential tremor: evidence for overactivity of cerebellar connections. *Ann Neurol* 1993;34:82–90.
- Lamarre Y. Animal models of physiological, essential and parkinsonian-like tremors. In: Findley LJ, Capildeo R, editors. *Movement disorders: tremor*. London: Macmillan Press; 1984. p. 183–94.
- Lauk M, Köster B, Timmer J, Guschlbauer B, Deuschl G, Lücking CH. Side-to-side correlation of muscle activity in physiological and pathological human tremors. *Clin Neurophysiol* 1999;110:1774–83.
- Llinás R, Volkind RA. The olivo-cerebellar system: functional properties as revealed by harmaline-induced tremor. *Exp Brain Res* 1973;18:69–87.
- Mima T, Hallett M. Electroencephalographic analysis of cortico-muscular coherence: reference effect, volume conduction and generator mechanism. *Clin Neurophysiol* 1999a;110:1892–9.
- Mima T, Hallett M. Corticomuscular coherence: a review. *J Clin Neurophysiol* 1999b;16:501–11.
- Murthy VN, Fetz EE. Synchronization of neurons during local field potential oscillations in sensorimotor cortex of awake monkeys. *J Neurophysiol* 1996;76:3968–82.
- Priestley M. *Spectral analysis and time series*. New York: Academic press; 1989.
- Raethjen J, Lindemann M, Schmaljohann H, Wenzelburger R, Pfister G, Deuschl G. Multiple oscillators are causing parkinsonian and essential tremor. *Mov Disord* 2000;15:84–94.
- Salenius S, Portin K, Kajola M, Salmelin R, Hari R. Cortical control of human motoneuron firing during isometric contraction. *J Neurophysiol* 1997;77:3401–5.
- Schuurman PR, Bosch DA, Bossuyt PM, Bonsel GJ, van Someren EJ, de Bie RM, Merkus MP, Speelman JD. A comparison of continuous thalamic stimulation and thalamotomy for suppression of severe tremor. *N Engl J Med* 2000;342:461–8.
- Timmer J. Modeling noisy time series: physiological tremor. *Int J Bifurcation Chaos* 1998;8:1505–16.
- Timmer J, Lauk M, Pfleger W, Deuschl G. Cross-spectral analysis of physiological tremor and muscle activity. I. Theory and application to unsynchronized electromyogram. *Biol Cybern* 1998a;78:349–57.
- Timmer J, Lauk M, Pfleger W, Deuschl G. Cross-spectral analysis of physiological tremor and muscle activity. II. Application to synchronized electromyogram. *Biol Cybern* 1998b;78:359–68.